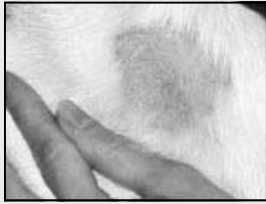


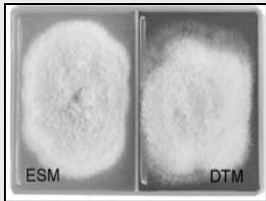
DermatoPlate Duo™ DTM Culture Plate Procedure




Gently pluck broken hairs and scale from periphery of skin lesion with a clean forceps or hemostat.



Distribute sample over both sides of DermatoPlate-Duo pushing a few strands down into the agar. Incubate at room temperature.



Check plates daily for growth and color change. At first sign of growth perform microscopic exam. If no growth occurs after 14 days the culture is considered negative.

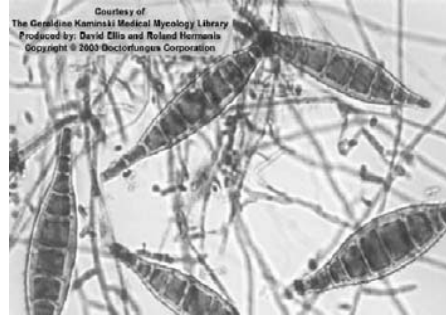


Place a drop of Lactophenol Cotton Blue stain on a slide and sample plate growth by gently touching with a Fungitape® loop and transferring to the slide.

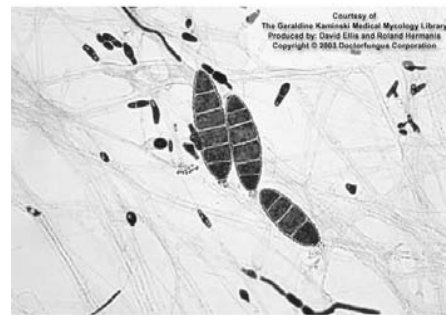

Carefully smooth tape over slide and observe at 10X and 40X power for characteristic micro- and macroconidia.

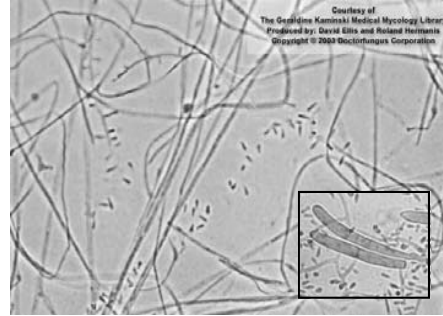
Fungitape is a registered trademark of Scientific Device Labs



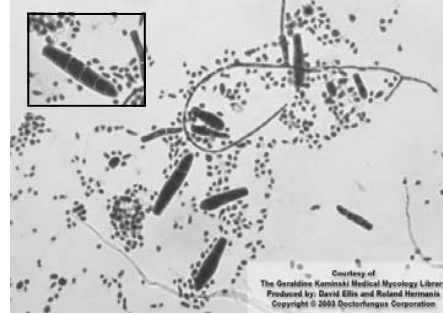
Microsporium canis produces 6-15 celled spindle shape macroconidia with rough outer walls and thinner septal walls. An asymmetrical apical knob may be present. Though rarely seen, microconidia are unicellular and pyriform (pear-shaped). *M. canis* can infect dogs, cats, and humans.



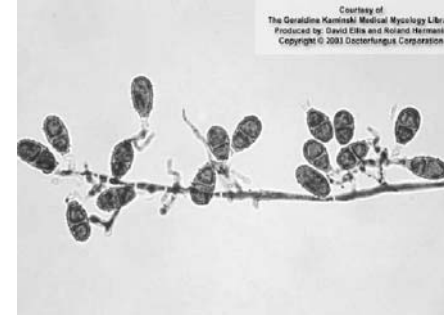
Microsporium gypseum produces elliptical to fusiform (spindle-shaped) macroconidia containing 3-6 cells. The distal ends are typically rounded and the thin outer walls are slightly roughened. They are likely to be seen in abundance. When observed, microconidia are club-shaped and will usually be seen attached to the hyphae. *Microsporium gypseum* can infect dogs, cats, and humans.



Trichophyton rubrum produces slender club-shaped to pyriform microconidia usually attached singly to the hyphae. Though rarely seen, macroconidia (insert) will be club-shaped with thin walls. *T. rubrum* is primarily a human pathogen and is rarely seen in animals.

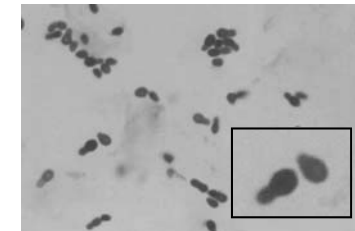


Trichophyton mentogrophytes produces both microconidia and macroconidia. Though rarely seen, macroconidia will be club to cigar shaped with thin walls and 2-5 cells. More commonly observed are abundant single-celled predominantly spherical microconidia that may or may not be attached to the hyphae. *T. mentogrophytes* can infect dogs, cats, and humans.



Microsporium nanum produces small oval to pyriform thin-walled macroconidia with 1-3 cells. Microconidia when present are club-shaped. *M. nanum* is primarily found in swine but humans in contact with swine can also become infected.

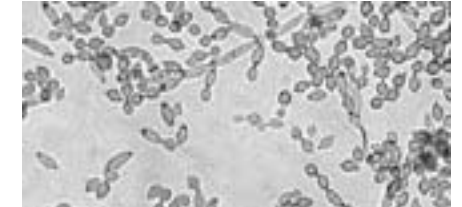
Cutaneous Yeast Infection



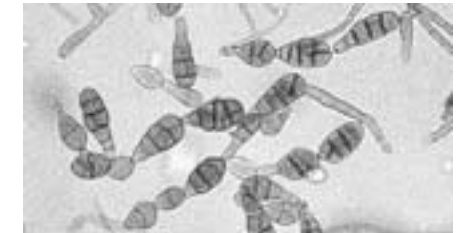Mallesezia pachydermatis is a yeast organism that will appear in skin scrapings or impression smears as clusters of thick-walled round to oval budding cells that stain blue with Diff-Quik® or Lactophenol Cotton Blue stain. *M. pachydermatis* is often associated with chronic otitis and may be a primary or secondary agent. Positive smears are considered diagnostic.

Non-Dermatophyte Fungi

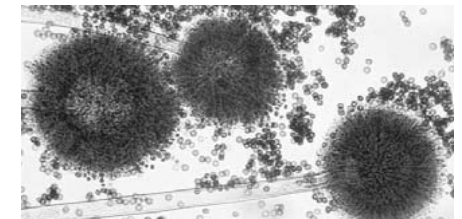
Although these organisms are considered contaminants, they can cause infections. They should be regarded as biohazards and disposed of appropriately.



Cladosporium cladosporioides produces single-celled conidia arising from specialized hyphae called conidiophores. The "shield-shaped" conidia are pale brown to dark brown and have a distinct dark hilus. They often form long chains from which the individual conidia can become detached.



Alternaria alternata produces multicelled conidia that emerge from simple, sometimes branched conidiophores. The conidia are pale brown, oval to teardrop shaped, smooth-walled and may occur in chains.



Aspergillus niger produces conidia that develop within a large conidial head at the tip of the conidiophores. The conidial heads are dark brown and the individual conidia as they break off are rounded, dark brown to black, with rough walls.

Photos courtesy of the Geraldine Kaminski Medical Mycology Library produced by David Ellis and Roland Hermanis.